

CASE REPORT

Pneumomediastinum After Difficult Vaginal Delivery

Ahmet Sızlanan¹, Onur Akçay²¹Clinic of Chest Surgery, Mardin State Hospital, Mardin, Turkey²Clinic of Chest Surgery, Kızıltepe State Hospital, Mardin, Turkey

Abstract

17-year-old primigravida patient presented with chest pain, dyspnea, sore throat and a sensation of swelling in the neck and throat approximately 3 hours after difficult vaginal delivery at home. Breath sounds were equal bilaterally. Physical examination revealed subcutaneous emphysema that expanded from the anterior thorax to the neck. Posteroanterior (PA) chest X-ray showed air in the neck and thoracic computed tomography showed pneumomediastinum. The patient was admitted to our clinic and was started on ampicillin-sulbactam 3 x 1 grams iv, paracetamol 2 x 1000 mg and 3 L/min of oxygen therapy. C-reactive protein (CRP) concentration and erythrocyte sedimentation rate (ESR), which were monitored on a daily basis, showed decline. Repeated chest X-rays did not show any progression. The patient was clinically stable and was discharged from the hospital on the third day. Currently in her third month of follow-up, the patient is stable.

KEYWORDS: Delivery, pneumomediastinum, pneumothorax**Received:** 08.05.2015**Accepted:** 29.05.2015

INTRODUCTION

Spontaneous pneumomediastinum is defined as free air in the mediastinum without trauma or a medical problem, and is rarely encountered [1,2]. Spontaneous pneumomediastinum is a clinical entity first described by Hamman in 1939 [3]. Conditions that increase intrathoracic pressure, such as esophageal rupture, acute asthma attack and trauma can be named as its reasons [4]. This study presents the case of spontaneous pneumomediastinum and pneumothorax that developed in a patient who had difficult vaginal delivery at home by reviewing the literature.

CASE PRESENTATION

17-year-old primigravida patient applied to our center with chest pain, dyspnea, sore throat and a sensation of swelling in the neck and throat approximately 3 hours after difficult vaginal delivery at home. Breath sounds were equal bilaterally. Physical examination revealed subcutaneous emphysema that expanded from the anterior thorax to the neck. Other physical examinations were evaluated normal. Leucocytosis was present in complete blood count during admission. It was seen that the patient's erythrocyte sedimentation rate (ESR) and CRP values were raised. Images consistent with subcutaneous emphysema in the neck (Figure 1) were seen in the postero-anterior chest X-ray (PA CX), and an image belonging to pneumomediastinum and bilateral minimum pneumothorax was assessed present on Thoracic Computed Tomography (CT) (Figures 2A,B). The patient, who was admitted to our clinic, was started on ampicillin sulbactam 3 x 1 grams iv, paracetamol 2 x 1000 mg and 3 L/min of oxygen therapy. It was seen in daily CRP and ESR follow-ups that there was a decline. Progression was not seen in PA AC graphy follow-ups. The clinically stable patient was discharged on day 3. The patient, who is currently on her third month follow-up, is stable.

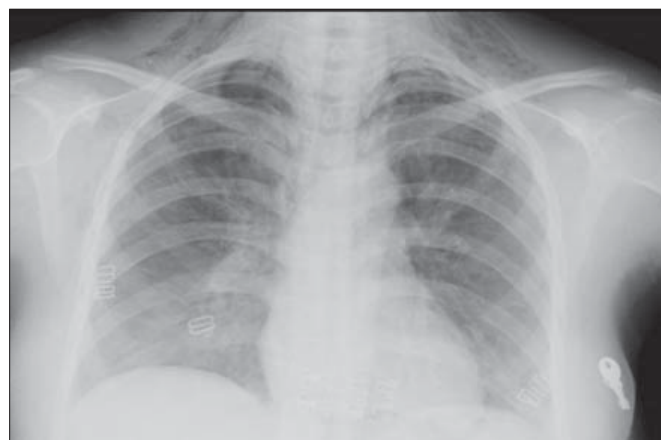


Figure 1. P-A chest X-ray showing subcutaneous emphysema in the neck.



Address for Correspondence: Onur Akçay, Kızıltepe Devlet Hastanesi,
Göğüs Cerrahisi Kliniği, Mardin, Türkiye E-mail: onur_akcay@yahoo.com
©Copyright 2016 by Turkish Thoracic Society - Available online at www.toraks.dergisi.org

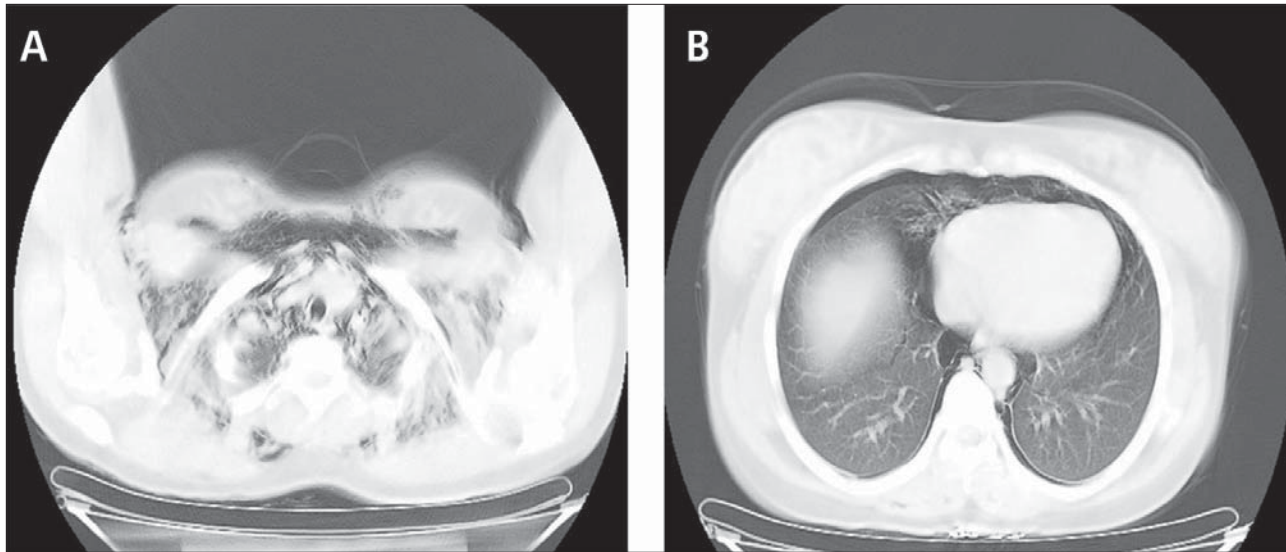


Figure 2. Thoracic CT image.

DISCUSSION

Apart from trauma, spontaneous pneumomediastinum and spontaneous pneumothorax that develop during pregnancy and maternity are rare occurrences [5,6]. Generally chest pain which is present in the clinical symptoms of the patients is accompanied with dyspnoea, dysphonia and subcutaneous emphysema in the neck [7]. Complaints start during delivery or immediately postpartum; however, this condition can be described as far as the postpartum second month [4]. Since the risk of venous thromboembolism increases in pregnant women, the risk of pulmonary thromboembolism also increases in the postpartum period, and pulmonary thromboembolism should be kept in mind in patients presenting with dyspnoea in the postpartum period [7,8]. The patient's complaints began approximately three hours postpartum, and the patient presented to our clinic with chest pain, dyspnea and subcutaneous emphysema in the neck region, which are findings also seen in the literature.

Many lung diseases including bronchiectasis, asthma, emphysema, and interstitial lung diseases are predisposing factors in the development of spontaneous pneumomediastinum [1]. These diseases that can cause spontaneous pneumomediastinum were not present in our patient.

Subcutaneous emphysema spreading to the neck is observed in Boerhaave syndrome originating from the oesophagus tissue. While Boerhaave syndrome is associated with vomiting during pregnancy, it has not been described during delivery. The source of free air in spontaneous pneumomediastinum is the lungs. Ruptures in small bronchial or alveolar level and barotrauma caused by positive pressure ventilation in the perinatal period can develop as a result of Valsalva-type manoeuvre that increase intraluminal pressure [7]. Prolonging of the second phase of delivery or the presence of cephalopelvic disproportion increases the risk of spontaneous pneumomediastinum development since intrathoracic pressure is going to increase due to the fact that the Valsalva manoeuvre will be specifically more in this period [4]. It was stated that our patient had a difficult delivery outside hospital conditions.

The diagnosis of spontaneous pneumomediastinum is made through chest roentgenogram or thoracic CT. Moreover, esophagogastrosopy and bronchoscopy are among the recommended diagnostic tests [1]. Chest roentgenogram and thoracic CT were performed on our patient but esophagogastrosopy and bronchoscopy could not be performed.

Follow-up period of these patients should be at least 24 to 36 hours [9]. Bed rest, oxygen inhalation, analgesic treatment, and antibiotherapy against the risk of mediastinitis are recommended in treatment [4,10,11]. Our case was followed up 48 hours in hospital conditions, and oxygen inhalation, analgesic treatment and prophylactic antibiotherapy were carried out throughout the follow-up.

Pneumothorax and spontaneous pneumomediastinum should rank among diagnosis in dyspnea complaint that could develop after difficult vaginal delivery.

Author Contributions: Concept - A.S., O.A.; Design - A.S., O.A.; Supervision - A.S., O.A.; Resources - A.S.; Materials - A.S.; Data Collection and/or Processing - O.A.; Analysis and/or Interpretation - A.S., O.A.; Literature Search - A.S., O.A.; Writing Manuscript - A.S., O.A.; Critical Review - A.S., O.A.

Conflict of Interest: No conflict of interest was declared by the authors.

Financial Disclosure: The authors declared that this study has received no financial support.

REFERENCES

1. Beynon F, Mearns S. Spontaneous pneumomediastinum following normal labour. *BMJ Case Reports* 2011. doi: 10.1136/bcr.07.2011.4556. [\[CrossRef\]](#)
2. Bilgin M, Kahraman C, Akçali Y, et al. Spontan pnömomediasten *Toraks Dergisi* 2003;4:183-5.
3. Hamman L. Spontaneous mediastinal emphysema. *Bull Johns Hopkins Hosp* 1939;64:1.

4. McGregor A, Ogwu C, Uppal T, et al. Spontaneous subcutaneous emphysema and pneumomediastinum during second stage of labour. *BMJ Case Reports* 2011. doi: 10.1136/bcr.04.2011.4067 [\[CrossRef\]](#)
5. Akçay O, Uysal A, Samancılar O, et al. An unusual emergency condition in pregnancy: pneumothorax. Case series and review of the literature. *Arch Gynecol Obstet* 2013;287:391-4. [\[CrossRef\]](#)
6. Norzilawati MN, Shuhaila A, Zainul Rashid MR. Postpartum pneumomediastinum. *Singapore Med J* 2007;48:174-6. [\[CrossRef\]](#)
7. Fraser W. Pneumomediastinum during spontaneous vaginal delivery. *Ann Thorac Surg* 2002;73:314-5. [\[CrossRef\]](#)
8. ACOG Committee on Practice Bulletins-Obstetrics. ACOG practice bulletin. Thrombembolism in pregnancy. *Int J Gynaecol Obstet* 2001;75:203-12. [\[CrossRef\]](#)
9. Ralph-Edwards AC, Pearson FG. Atypical presentation of spontaneous pneumomediastinum. *Ann Thorac Surg* 1994;58:1758-60. [\[CrossRef\]](#)
10. Iyer VN, Joshi AY, Ryu JH. Spontaneous pneumomediastinum: analysis of 62 consecutive adult patients. *Mayo Clin Proc* May 2009;84:417-21. [\[CrossRef\]](#)
11. Caceres M, Ali SZ, Braud R, et al. Spontaneous pneumomediastinum: a benign curiosity or a significant problem. *Chest* 2005;128:3298-302. [\[CrossRef\]](#)